www.propofology.com

ECHO
HEART VIEWS

Dr. David Lyness
@Gas_Craic

Phased Array Probe

Probe Marker Points Toward...
SLAX – Left Side of Pt
SIVC –Left then Head
PLAX – Right Shoulder
PSAX – Left Shoulder
A4CH – Axilla
Arrows = Marker Direction

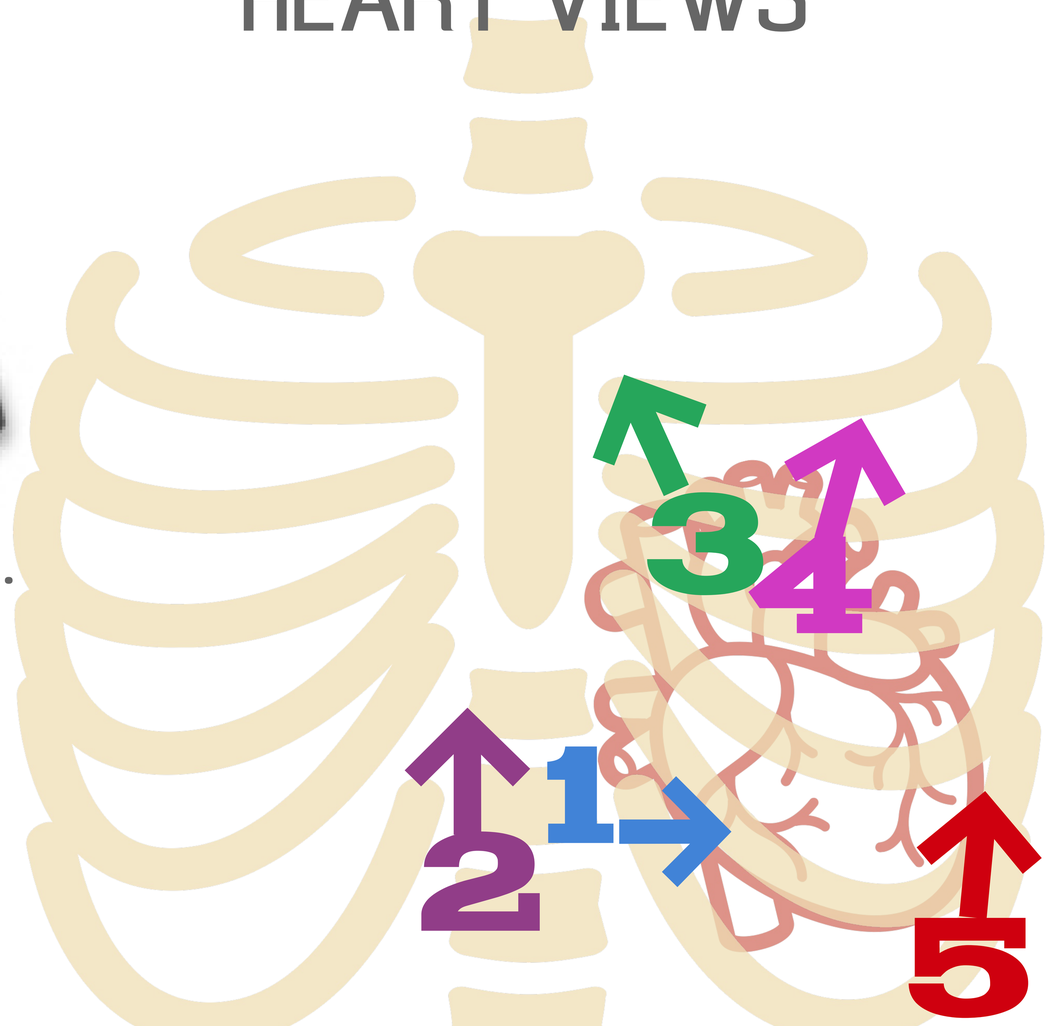

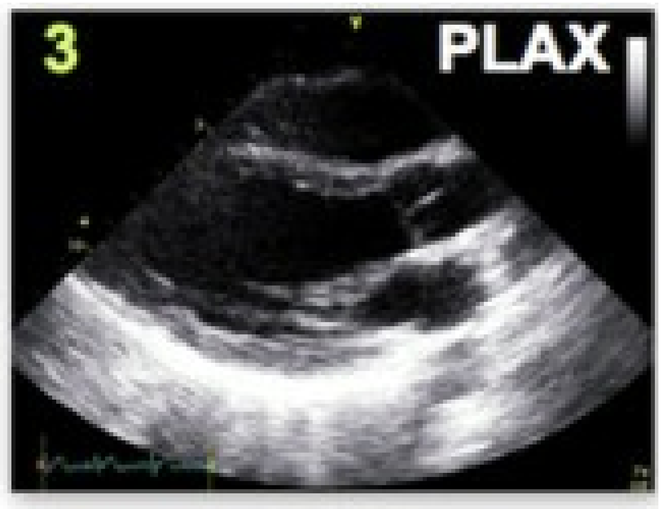

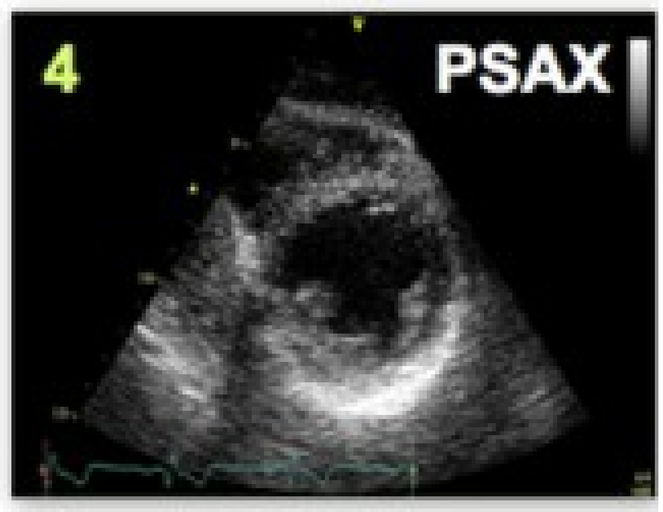

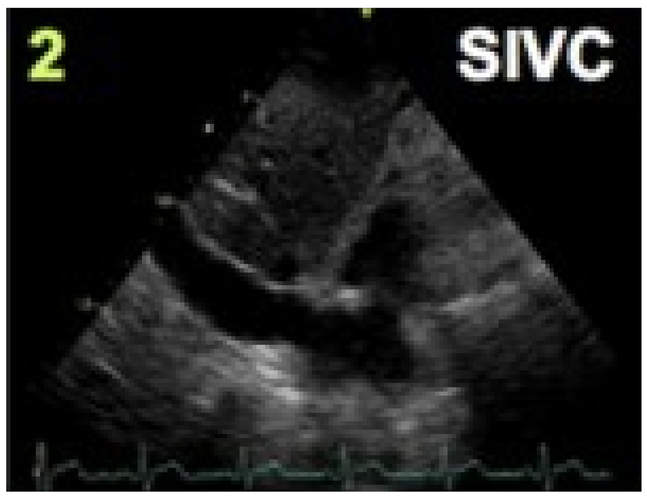

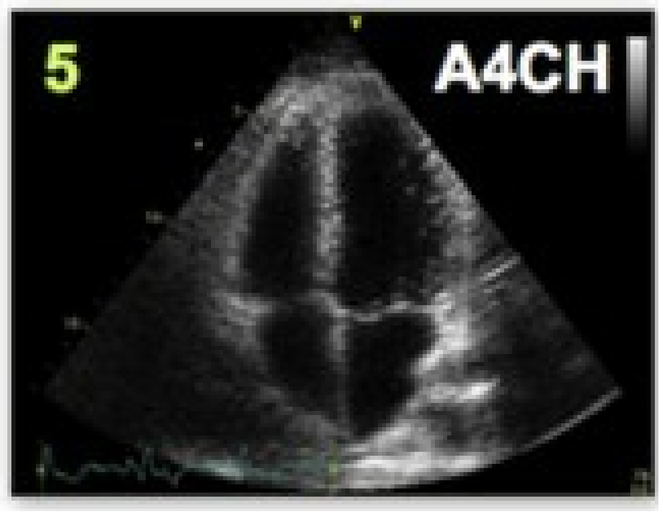

PLUG IN THE ECG TRACER!

1. Subcostal Long Axis - Liver, Chambers & Valves
2. Subcostal Short Axis - IVC View - Liver, RA and IVC
3. Parasternal Long Axis -LA, RA, LVOT, MV, LV, RV
4. Parasternal Short Axis - shows MV in a circular LV
5. Apical 4 Chamber

1. Name & Date Study on Scanner
2. Plenty of Gel
3. Always use the marker
4. Sit if necessary
5. Reduce depth when needed

SLAX – marker to left
-Comare chamber sizes.
-RA> or equal to LA
-RV <2/3 of LV
-Atria <2/3 of Ventricles
-RV wraps around LV, contracting and twisting
-RV annulus to apex reduction in chamber size
-LV compare opposing walls at different segments
-Minimal pericardial space (echo free)

SSAX/SIVC - marker to left then twist to head
Find right atrium and twist probe to find IVC
You will also see hepatic veins
Lung will be in the inferior portion of the screen

TAPSE in A4C View - Tricuspid Annular Plane Systolic Excursion
M-Mode across lateral tricuspid annulus
This measures the displacement of the valve at peak systole
A value of >20mm could be a normal value
This is a crude estimate of RVSF- probe dependent, LV dependent and how much the heart is moving overall.

MAPSE in A4C View - Mitral Annular Plane Systolic Excursion
M-Mode across lateral mitral annulus
A value of >10mm could be normal
This is a crude estimate of LVSF- only longitudinal, view dependent, inaccurate with regional wall abnormalities

PLAX - marker toward right shoulder
RV = AV = LA in size in PLAX = ~<4cm
LV <5.8cm and walls should contract similarly

PSAX - marker towards left shoulder
Should show mitral valve in a circular LV
Should be able to see papillary muscle
Muscle should contract equally around the circle.

A4C - marker toward axilla
LA > RA (marginally)
RV <2/3 of LV
RV ends before LV (apex of each chamber)
Atria <2/3 of Ventricles
Ventricles look to have similar function
RV contracts and twists, annulus to apex
LV compare opposing walls at different segments
AV Valves have similar density and function
Normal = you cannot see the pericardial space

These Are Normal Reference Points

Sources:
FICE
http://www.criticalusg.pl/en/echo
Oli Flower's Video Tutorials on Views
WikiEcho.org